Scientific African 3 (2019) e00068

Contents lists available at ScienceDirect

Scientific African

journal homepage: www.elsevier.com/locate/sciaf

Acute toxicity, oxidative stress response and clinicopathological changes in Wistar rats exposed to aqueous extract of *Uvaria chamae* leaves

S.A. Ejeh[a], S.E. Abalaka[b,*], I.L. Usende[c], Y.A. Alimi[a], F.O. Oyelowo[c]

[a] Department of Veterinary Physiology and Biochemistry, University of Abuja, Abuja, Nigeria
[b] Department of Veterinary Pathology, University of Abuja, Abuja, Nigeria
[c] Department of Veterinary Anatomy, University of Abuja, Abuja, Nigeria

ARTICLE INFO

Article history:
Received 31 December 2018
Revised 4 April 2019
Accepted 9 April 2019

Keywords:
Uvaria chamae
Wistar rats
Toxicity
Oxidative stress
Clinicopathology

ABSTRACT

Acute toxicity, oxidative stress damage and clinicopathological changes were investigated in Wistar rats exposed to the aqueous extract of *Uvaria chamae* leaves because of the widespread ethnomedicinal use of the plant in many parts of the world. The acclimatized rats were administration 10 $mgkg^{-1}$, 100 $mgkg^{-1}$ and 1000 $mgkg^{-1}$ (Phase I) and 1600 $mgkg^{-1}$, 2900 $mgkg^{-1}$ and 5000 $mgkg^{-1}$ of the extract (Phase II). We observed rats for signs of toxicity within the first 30 min, 1-h, 2-h, 3-h, 4-h, 12-h, 24-h and thereafter daily for 14 days. Body and organ weights of rats were also monitored and used as measures of toxicity. We evaluated the haematological, biochemical, antioxidant and lipid peroxidation as well as histopathological effects of the extract in experimental rats after day 14th of the exposure. Exposed rats showed no signs of toxicity. The median lethal dose of the extract was estimated to be above 5000 $mgkg^{-1}$. We observed significant ($p < 0.05$) weight gain in pooled body weights of rats at the end of the experiment but this was significant ($p < 0.05$) in Phase I only. There were no significant ($p > 0.05$) differences in the haematological and biochemical profiles as well as in the antioxidant and lipid peroxidative activities of the extract in exposed rats. Similarly, no obvious histopathological changes were observed in exposed rats. Although the aqueous extract of *U. Chamae* leaves was apparently non-toxic to the exposed rats as demonstrated, there is still a need for further investigations of its prolonged use and at sub-chronic extract concentrations.

© 2019 The Authors. Published by Elsevier B.V. on behalf of African Institute of Mathematical Sciences / Next Einstein Initiative.
This is an open access article under the CC BY license.
(http://creativecommons.org/licenses/by/4.0/)

Introduction

The plant kingdom is an enormous reservoir of biologically active compounds with various chemical structures and protective/disease preventive properties [1]. That is why natural products are and have remained the cornerstone of our health care system [2] with about 80% of the world's population still relying on traditional medicine for their health care needs [3]. However, these valuable medicinal resources are largely untapped because of inadequate scientific, technical and com-

* Corresponding author.
E-mail address: seabalaka@yahoo.co.uk (S.E. Abalaka).

https://doi.org/10.1016/j.sciaf.2019.e00068
2468-2276/© 2019 The Authors. Published by Elsevier B.V. on behalf of African Institute of Mathematical Sciences / Next Einstein Initiative. This is an open access article under the CC BY license. (http://creativecommons.org/licenses/by/4.0/)

mercial infrastructure in developing countries [4] hence the need for the present study. This is because medicinal properties of plants are due to their phytochemical constituents, but some of these constituents may also be toxic to final consumers of such plants [2] via oxidative and cellular damages. That is why we must strive to achieve a balance between a medicinal plant's efficaciousness and its safety because of what use is a plant that is safe but lack efficacy or a plant that is of therapeutic value but highly toxic or harmful [5].

The present work focused on preliminary investigation of toxic effects of aqueous extract of *Uvaria chamae* leaves to exposed Wistar rats as a precursor to other investigations into the ethnomedicinal importance of the plant. This is because the leaf juice of *U. chamae* has reportedly been used to treat injuries, swellings, ophthalmia irritis and conjuctivitis [6] while jaundice, intermittent fever, dysentery, severe abdominal pain, hepatitis and conjunctivitis have been treated with various preparations of the plant [7]. An overriding concern in the selection of these herbal medicines for use in healthcare delivery is their safety as plants extracts should be not only efficacious but also safe for human consumption [8]. Therefore, there is a need to verify the safety level of the ethnomedicinal use of *U. chamae* hence the present study. Evaluation of haematological, serum biochemical and oxidative stress responses along with induced tissue histopathological changes in exposed animals are amongst the commonly used biomarkers of toxicity. This is because cellular damages normally precede death as obvious end-point of toxicity. The present work therefore, aimed to investigate haematological, biochemical, oxidative stress and histopathological changes in Wistar rats exposed to the aqueous extract of *U. chamae* leaves.

Materials and methods

Plant and animal preparations

The leaves of *U. Chamae* were collected from within Alkpali Ugbokolo town in Okpokwu Local Government Area of Benue State, Nigeria between September–October 2016. The leaves were identified by the Taxonomist (Mr. Namadi Sanusi) of the Herbarium of the Department of Biological Sciences, Ahmadu Bello University, Zaria with specimen voucher no. 3129. The leaves were washed under running tap water and dried in the laboratory at room temperature. This was pulverized into fine powder and macerated in distilled water for two days to obtain an aqueous filtrate that was then dried over water bath and stored in a refrigerator ready for use.

Adult Wistar rats of both sexes used for the experiment were acclimatized to laboratory condition for 14 days under natural 12/12 daylight and night photoperiod. Experimental rats were fed *ad libitum* with Broiler finisher (Livestock Feeds Plc, No. 1, Henry Carr Street, P. M. B. 21097, Ikeja, Lagos State, Nigeria) with a proximate compositions of protein - 18.0%; fats – 6.0%; Fibre – 6.0%; Calcium – 1.0%; average phosphorus – 0.45% and metabolizable energy – 2900 Kcal/kg. Fresh ample drinking water was provided twice daily throughout the period.

Acute toxicity bioassay

We performed the acute toxicity study of the aqueous extract of *U. Chamae* leaves in exposed Wistar rats as described by Lorke [9] with a slight modification regarding the use of three rats instead of one rat per group in Phase II of the experimental set-up. We used 21 Wistar rats of both sexes with average body weight of 141.4 ± 5.55 g for the study. Phase I of the experiment involved the oral dosing (by gavage) of three rats each with 10 $mgkg^{-1}$, 100 $mgkg^{-1}$ and 1000 $mgkg^{-1}$ of the extract. These were then observed for signs of toxicity within the first 30 min, 1-h, 2-h, 3-h, 4-h and 12-h, respectively and daily thereafter for 14 days for signs of delayed toxicity according to OECD [10]. However, another set of three rats were dosed orally with distilled water and served as the control group. We proceeded to dose another set of Wistar rats at 1600 $mgkg^{-1}$, 2900 $mgkg^{-1}$ and 5000 $mgkg^{-1}$ of the extract, respectively for the second Phase II of the experiment due to the absence of mortality after 24-h of exposure in Phase I of the experimental set-up. The median lethal dose (LD_{50}) of the aqueous extract *U. chamae* leaves in exposed Wistar rats was calculated as the geometric mean of the dose that did not produce mortality and the highest dose that produced mortality where there was mortality but estimated to be above the highest dose exposure if no mortality was recorded according to [9]. Changes in body weights monitored at the beginning and at the end of the experiment were also used as index of toxicity [11,12].

Haematological evaluation

At the end of each 14th day observational period for both Phases of the experimental set-up, heparized capillary tubes were used to collect blood from the retro-orbital plexus of the lateral canthus of the eye of each rat into heparin containing sample bottles for haematological analyses. We evaluated full blood count in experimental rats using an automatic haematology analyser (BC-2800Vet, Mindray auto haematology analyser, www.mindray.com).

Biochemical evaluation

Blood was collected from the lateral canthus of the eye of each rat with heparinised capillary tubes into plain sample bottles for serum chemistry analysis at the end of the 14 days observational period following the extract exposure. The

collected blood were allowed to clot at room temperature and centrifuged at 3000 *g* for 30 min to obtain the serum. The alanine aminotransferase, aspartate aminotransferase and alkaline phosphatase activities as well as the creatinine and urea levels were determined using commercial assay kits (Randox Laboratory Limited, United Kingdom) according to the manufacturer's protocol.

Oxidative stress determination

Similarly at the end of each 14 days observational period, experimental rats were euthanised with xylazine and ketamine combination as described by Usende et al. [13]. The liver was harvested from each dissected rat, dipped in normal saline, wiped dry with blotting paper and immediately weighed to determine liver absolute weight as well as getting the appropriate liver weight for preparing the liver homogenase. We prepared 10% homogenase of each liver in 50Mn phosphate buffer at pH 7.4 and used the methods of Fridovich [14] and Aebi [15] to determine superoxide dismutase (SOD) and catalase (CAT) activities. Similarly, we used the method of Ellman [16] as described by Rukkumani et al. [17] to determine the reduced glutathione (GSH) activity while the method of Ohkawa et al. [18] as described by Sivoňová et al. [19] was used to ascertain the extent of lipid peroxidation.

Absolute and relative liver weight determination

Each harvested liver was immediately weighed to get its absolute weight while its relative weight was calculated as described by Akhtar et al. [20] below:

$$\text{Relative liver weight} = \frac{\text{Liver weight (g)}}{\text{Body weight (g)}} \times 100$$

Histopathological determination

The harvested liver, spleen, kidney and heart of exposed rats were fixed in 10% neutral buffered formalin, paraffin embedded and sectioned at 5 µm prior to haematoxylin and eosin staining according to standard procedure described by Bancroft and Cook [21]. The prepared slides were viewed under light microscopy at varying magnifications for histopathological changes.

Statistical analysis

The obtained data were expressed as mean (±SEM) and some where then subjected to Student's *t*-test while others were subjected to One-way analysis of variance (ANOVA) for statistical significance ($p < 0.05$) between means using GraphPad software programme (GraphPad Prism version 4.0., www.graphpad.com).

Results

No death was recorded in both Phases of the experiment as shown in Table 1. We, therefore, estimated the LD_{50} of the orally administered aqueous extract of *U. chamae* leaves in the exposed Wistar rats to be > 5000 $mgkg^{-1}$. Pooled final body weight of experimental rats were significantly ($p < 0.05$) higher than their pooled initial weights as presented in Table 2. However, significant ($p < 0.05$) increase was recorded only in Phase I of the experimental set-up.

Table 1
Mortality pattern in Wistar rats orally administered aqueous extract of *Uvaria chamae* leaves by gavage.

Experiment	Dose ($mgkg^{-1}$)	Mortality	
		Day-0	Day-14
Control	0	0/3	0/3
Phase I	10	0/3	0/3
	100	0/3	0/3
	1000	0/3	0/3
Phase II**	1600	0/3	0/3
	2900	0/3	0/3
	5000	0/3	0/3

** Three rats per exposed group.

Table 2
The effect of aqueous extract of *Uvaria chamae* leaves on body weight of the exposed Wistar rats.

Body weight	Dose range (mgkg^{-1})	Weight gain (g)		
		Initial (0 days)	Final (14 days)	t-value
Pooled	0–5000	137.0 ± 4.97	168.9 ± 5.79	0.0002*
Phase I	0–1000	135.3 ± 5.49	169.3 ± 6.92	0.0009*
Phase II**	1600–5000	139.3 ± 9.34	168.3 ± 10.37	0.0542

* Values with asterisks within rows are statistically significant ($p < 0.05$).
** Three rats per exposed group.

Table 3
The effect of aqueous extract of *Uvaria chamae* leaves on the haematological profile of the exposed Wistar rats.

Parameters	Extract dose						
	Control	Phase I			Phase II		
		10 (mgkg^{-1})	100 (mgkg^{-1})	1000 (mgkg^{-1})	1600* (mgkg^{-1})	2900* (mgkg^{-1})	5000* (mgkg^{-1})
RBC (x 10^{12} L^{-1})	7.83 ± 0.62	8.33 ± 0.23	8.02 ± 0.04	8.42 ± 0.02	7.64 ± 0.13	7.63 ± 0.26	7.40 ± 0.17
PCV(11^{-1})	0.41 ± 0.02	0.44 ± 0.00	0.41 ± 0.00	0.44 ± 0.02	0.40 ± 0.01	0.40 ± 0.02	0.31 ± 0.07
Hb (gL^{-1})	139.30 ± 8.19	151.00 ± 2.00	144.00 ± 2.52	151.50 ± 5.50	141.30 ± 3.48	141.70 ± 7.31	140.0 ± 3.00
MCV (fL)	52.67 ± 1.76	57.00 ± 2.00	55.62 ± 0.33	57.50 ± 3.50	50.67 ± 0.88	52.67 ± 2.03	53.00 ± 1.00
MCH (pg)	17.90 ± 0.45	71.90 ± 0.50	17.90 ± 0.20	17.95 ± 0.65	17.93 ± 0.43	18.53 ± 0.55	18.55 ± 0.45
MCHC (gL^{-1})	388.00 ± 5.03	335.00 ± 4.00	341.70 ± 3.84	332.00 ± 8.00	354.00 ± 8.02	353.30 ± 1.86	350.50 ± 3.50
WBC (x 10^9 L^{-1})	10.42 ± 3.59	13.26 ± 0.70	13.86 ± 3.21	8.26 ± 1.66	10.22 ± 1.74	9.19 ± 1.25	7.81 ± 3.50
LYMPH (x 10^9 L^{-1})	7.49 ± 2.51	8.83 ± 0.48	10.47 ± 2.47	5.02 ± 1.47	6.50 ± 0.60	6.01 ± 0.17	6.20 ± 3.03
NEUT (x 10^9 L^{-1})	2.09 ± 0.83	3.16 ± 0.94	1.96 ± 0.44	2.72 ± 0.27	2.54 ± 0.87	2.02 ± 0.64	0.68 ± 0.04
EOSIN & BASOP (x 10^9 L^{-1})	0.85 ± 0.8	1.28 ± 0.3	1.44 ± 0.3	0.52 ± 0.1	1.19 ± 0.3	1.29 ± 0.6	0.90 ± 0.4

Values with different superscripts within rows are statistically significant ($p < 0.05$).
*Conducted with three rats per group
RBC – Red blood cell, PCV – Packed cell volume; Hb – Haemoglobin; MCV – Mean corpuscular volume; MCH – Mean corpuscular haemoglobin; MCHC – Mean corpuscular haemoglobin concentration; WBC – White blood cell; LYMPH - Lymphocyte; NUET – Neutrophil; EOSIN – Eosinophil; BASOP – Basophil.

Table 4
Biochemical changes in Wistar rats exposed to the aqueous extract of *Uvaria chamae* leaves.

Parameters	Extract dose						
	Control	Phase I			Phase II		
		10 (mgkg^{-1})	100 (mgkg^{-1})	1000 (mgkg^{-1})	1600* (mgkg^{-1})	2900* (mgkg^{-1})	5000* (mgkg^{-1})
ALT (IU)	9.39 ± 3.22	12.56 ± 4.59	16.26 ± 3.38	13.94 ± 0.26	11.53 ± 0.87	10.14 ± 1.54	10.84 ± 2.60
AST (IU)	21.33 ± 2.85	19.20 ± 1.75	18.52 ± 9.74	14.53 ± 1.40	12.72 ± 5.82	17.55 ± 6.71	9.23 ± 3.38
ALP (IU)	659.20 ± 83.35	453.00 ± 48.22	427.30 ± 11.37	440.90 ± 53.47	554.00 ± 72.10	427.10 ± 3 89	521.30 ± 69.45
Urea (µmol/L)	6.03 ± 0.31	6.33 ± 0.73	6.41 ± 0.10	6.78 ± 0.05	7.09 ± 0.73	6.46 ± 1.11	8.69 ± 1.97
Creatinine (µmol/L)	37.45 ± 4.40	46.43 ± 0.79	41.95 ± 4.66	40.46 ± 2.59	45.88 ± 2.48	47.26 ± 0.03	44.51 ± 1.94

Values with different superscripts within rows are statistically significant ($p < 0.05$).
*Conducted with three rats per group.
ALT - Alanine aminotransferase; AST - Aspartate aminotransferase; ALP - Alkaline.

Table 5
Oxidative stress and lipid peroxidation effect of aqueous extract of *Uvaria chamae* leaves in the exposed Wistar rats.

Parameters	Extract dose						
	Control	Phase I			Phase II		
		10 (mgkg^{-1})	100 (mgkg^{-1})	1000 (mgkg^{-1})	1600* (mgkg^{-1})	2900* (mgkg^{-1})	5000* (mgkg^{-1})
SOD (U/mg protein)	11.48 ± 0.37	10.01 ± 1.03	6.28 ± 2.80	8.27 ± 0.30	10.39 ± 1.32	11.67 ± 0.42	9.53 ± 1.70
CAT (U/mg protein)	69.05 ± 5.47	42.43 ± 28.80	79.11 ± 14.47	82.03 ± 7.20	35.27 ± 10.37	39.91 ± 11.44	35.86 ± 8.75
GSH (U/mg protein)	17.02 ± 0.28	20.97 ± 2.24	17.94 ± 0.26	18.37 ± 0.47	26.12 ± 4.40	23.42 ± 3.17	38.58 ± 15.5
MAD (U/mg protein)	2232.13 ± 9.12	2253.40 ± 91.46	2561.67 ± 460.20	3229.40 ± 62.78	2340.53 ± 305.20	2704.03 ± 497.20	2831.13 ± 478.30

Values with different superscripts within rows are statistically significant ($p < 0.05$).
*Conducted with three rats per group.
SOD – Superoxide dismutase; CAT – Catalase; GSH – Reduced glutathione; MAD – Malondialdehyde.

Table 6
Absolute liver weight and relative liver weight in Wistar rats orally administered aqueous extract of *Uvaria chamae* leaves by gavage.

Organ weight	Extract dose						
	Control	10 $mgkg^{-1}$	100 $mgkg^{-1}$	1000 $mgkg^{-1}$	1600* $mgkg^{-1}$	2900* $mgkg^{-1}$	5000* $mgkg^{-1}$
ALW	5.00 ±0.57	5.67 ±0.33	6.33 ±0.33	6.33 ±0.67	5.33 ±1.45	6.67 ±1.33	6.67 ±1.45
RLW	3.47 ±0.38	3.30 ±0.40	3.22 ±0.29	3.49 ±0.04	3.19 ±0.53	3.62 ±0.38	3.52 ±1.66

Values with same superscripts within rows are statistically insignificant ($p < 0.05$).
* Conducted with three rats per group.
ALW – Absolute liver weight; RLW – Relative liver weight.

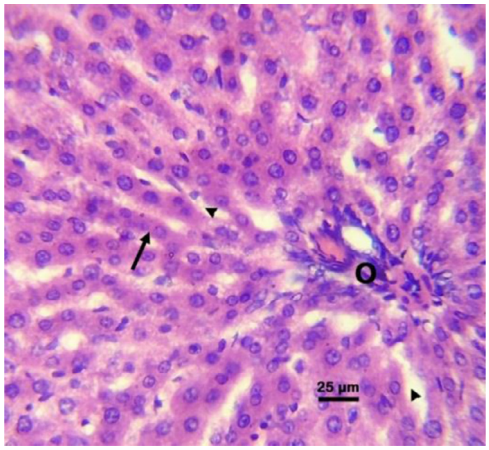

Fig. 1. The photomicrograph of the liver of a control Wistar rat in aqueous extract of *Uvaria chamae* leaves exposure showing the portal triad (O), hepatic cord (arrow) and hepatic sinusoid (arrow heads). H & E.

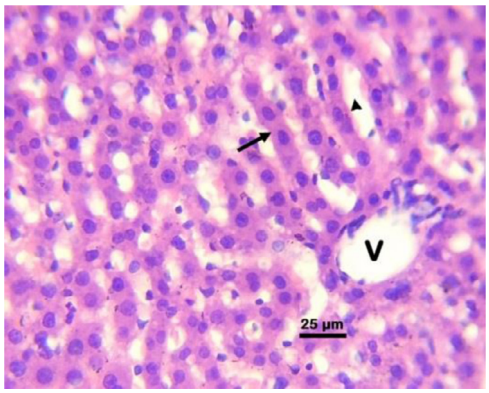

Fig. 2. The photomicrograph of the liver of a Wistar rat exposed to 5000 $mgkg^{-1}$ of the aqueous extract of *Uvaria chamae* showing the central vein (V), hepatic cord (arrow) and hepatic sinusoid (arrow head). H & E.

Changes in the haematological profile of the exposed rats were as presented in Tables 3. These changes were neither concentration-dependent nor significant ($p > 0.05$) with increasing extract concentrations. No significant ($p > 0.05$) changes were recorded in serum ALT, AST and ALP activities, including those of serum creatinine and urea levels in the exposed rats as shown in Table 4. Although we recorded decreased SOD and CAT activities viz-a-viz increased GSH and MAD activities with increasing extract concentrations, these changes were neither significant ($p > 0.05$) nor concentration dependent as shown in Table 5. There were no significant ($p > 0.05$) differences in absolute liver weights and relative liver weights of the experimental rats with increasing extract concentrations as presented in Table 6. Similarly, no obvious histopathological changes were observed in the liver, spleen, kidney and hearts of the exposed rats as presented in Figs. 1–8.

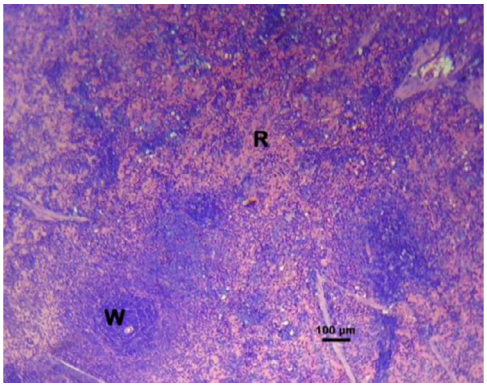

Fig. 3. The photomicrograph of the spleen of a control Wistar rat in aqueous extract of *Uvaria chamae* leaves exposure showing the red pulp (R) and the white pulp (W). H & E. (For interpretation of the references to color in this figure legend, the reader is referred to the web version of this article.)

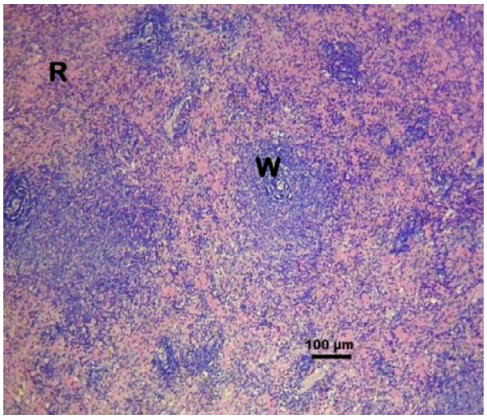

Fig. 4. The photomicrograph of the spleen of a Wistar rat exposed to 5000 $mgkg^{-1}$ of the aqueous extract of *Uvaria chamae* leaves showing the red pulp (R) and the white pulp (W). H & E. (For interpretation of the references to color in this figure legend, the reader is referred to the web version of this article.)

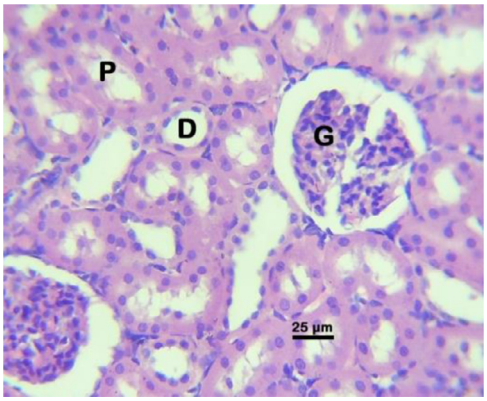

Fig. 5. The photomicrograph of the kidney of a control Wistar rat in aqueous extract of *Uvaria chamae* leaves exposure showing the glomerulus (G), proximal tubule (P) and the distal tubule (D). H & E.

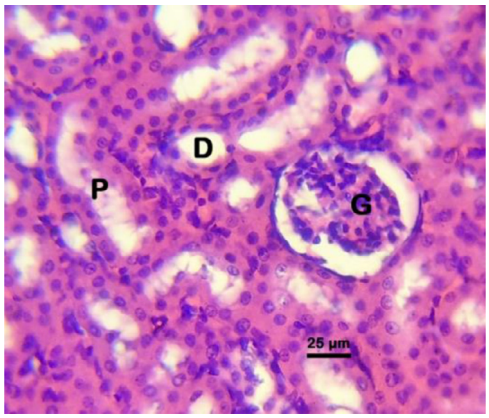

Fig. 6. The photomicrograph of the kidney of a Wistar rat exposed to 5000 mgkg^{-1} of the aqueous extract of *Uvaria chamae* leaves showing the glomerulus (G), proximal tubule (P) and the distal tubule (D). H & E.

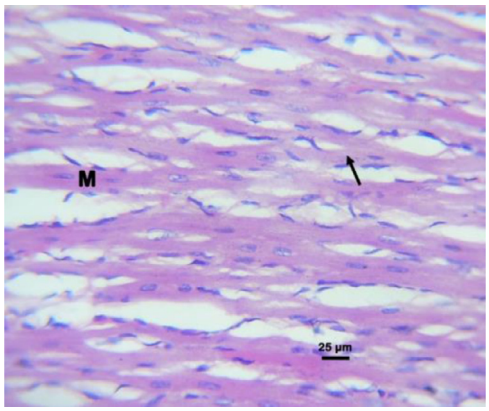

Fig. 7. The photomicrograph of the heart of a control Wistar rat in aqueous extract of *Uvaria chamae* leaves showing the muscle fibre (M) with the intercalated disc connection (arrow). H & E.

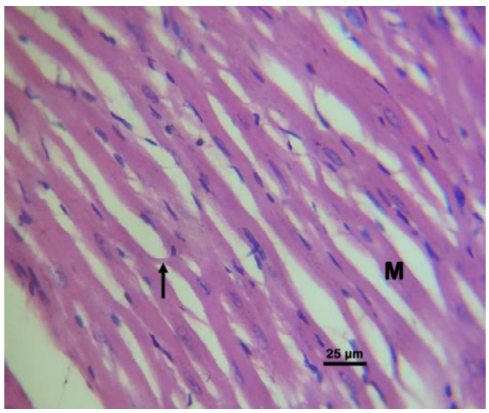

Fig. 8. The photomicrograph of the heart of a Wistar rat exposed to 5000 mgkg^{-1} of the aqueous extract of *Uvaria chamae* leaves showing the muscle fibre (M) with the intercalated disc connection (arrow). H & E.

Discussion

The absence of obvious signs of toxicity, including mortality as an end-point of toxicity at the highest extract concentrations showed that the LD_{50} of the aqueous extract of *U. Chamae* leaves was higher than 5000 mgkg^{-1} thereby making the extract relatively non-toxic in the exposed rats via the administered route according to Lorke [9]. This was because if an animal survives the 5000 mgkg^{-1} toxicant exposure, the LD_{50} will be estimated to be above 5000 mgkg^{-1} requiring no further

test above that concentration [9,22,23]. This meant that the extract was practically non-toxic according to the acute toxicity grading standard [24,25] thereby validating the folklore and ethnomedicinal use of the plant worldwide. The estimated LD_{50} value agreed with the reports of Onakpa [26] and Olumese *et al.* [6] who worked on parts of the plant in Wistar rats as well as those of Bila [27] and Emeka *et al.* [28] who worked on parts of the plant in mice with the exception of an LD_{50} of 692.82 $mgkg^{-1}$ reported in mice by Okon *et al.* [29]. The recorded significant ($p < 0.05$) weight gain in the pooled and in Phase I of the exposed rats also showed the extract's apparent lack of toxicity as there seems to be no obvious interference with appetite, digestion and assimilation of the consumed food in the exposed rats throughout the exposure periods. This is because significant ($p < 0.05$) weight loss is normally associated with toxic effect of substances in exposed animals [11,12]. The observed non-significant ($p > 0.05$) changes in both absolute and relative liver weights with increasing extract concentrations showed that the extract was apparently non-toxic to the exposed rats. This is because changes in organ weight can also be used as an index of toxicity in the absence of morphological changes [30]. However, The Society of Toxicologic Pathology is of the opinion that organ weights are of limited value and therefore, not recommended in studies in which only a single dose of substance was administered [31]. The non-significant ($p > 0.05$) changes in the haematological, biochemical and oxidative stress markers showed that the plant extract as administered was neither haemotoxic nor caused obvious cellular damages. Olumese *et al.* [32] reported significantly ($p < 0.05$) reduced MCHC and increased platelets with no significant ($p > 0.05$) changes in other haematological parameters of the exposed rats. Similarly, Okafor *et al.* [33] reported significant ($p < 0.05$) increase in ALP and significant ($p < 0.05$) reduction in urea with insignificant ($p > 0.05$) changes in ALt, AST and creatinine in exposed rats. The apparent lack of histopathological changes was also indicative of the non-toxic nature of the extract in exposed rats although Olumese *et al.* [6] reported mild vascular congestion with lymphocytic infiltration in the liver and kidney of rats exposed to the aqueous extract of the plant's leaf.

Conclusions

The inability of the extract to cause significant ($p > 0.05$) haemotoxicity, lipid peroxidation and oxidative stress damage, including biochemical and histopathological changes in the exposed rats further reinforced the estimated LD_{50} greater than 5000 $mgkg^{-1}$. This preliminary study has shown that the aqueous extract of *U. chamae* leaves is relatively safe as administered thereby lending credence to the ethnomedicinal importance of the plant in this part of the world. However, further investigations into repeated and prolonged exposures need to be conducted.

Acknowledgement

We acknowledge the immense contributions of the Mr. Tags, S. Z. of Gross Anatomy Unit, Department of Veterinary Anatomy, University of Abuja, Abuja, Nigeria.

Ethical declaration

The experiment complied with the UK Animals (Scientific Procedures) Act, 1986 and associated guidelines, EU Directive 2010/63/EU for animal experiments or the National Institutes of Health guide for the care and use of Laboratory animals (NIH Publications No. 8023, revised 1978.

Declaration of interest

None.

Funding

This research did not receive any specific grant from funding agencies in the public, commercial, or not-for profit sectors

References

[1] M.I. Builders, C.o. Isichie, J.C. Aguiyi, Toxicity studies of the extracts of *Parkia biglobosa* stem bark in rats, Br. J. Pharm. Res. 2 (1) (2012) 1–16.
[2] O.E. Adebiyi, M.O. Abata, Phytochemical and acute toxicity of ethanolic extract of *Enantia chlorantha* (olive) stem bark in albino rats, Interdiscipl. Toxicol. 6 (3) (2013) 145–151, doi:10.2478/intox-2013-0023.
[3] N.R. Farnsworth, O. Akerele, A.S. Bingel, D.D. Soejarto, Z. Guo, Medical plants in therapy, Bull. World Health Org. 63 (1985) 965–981.
[4] O. Akerele, Nature's medicinal bounty: Don't throw it away, World Health Forum 14 (4) (1993) 390–395.
[5] D.D. Moreira, S.S. Teixeira, M.H.D. Monteiro, A.C.A.X. De-Oliveira, F.J.R.P. Erratum, Traditional use and safety of herbal medicines, Rev. Bras. Farmacogn. 24 (2) (2014) 248–257.
[6] F.E. Olumese, I.O. Onoagbe, G.I. Eze, F.O. Omoruyi FO, Safety assessment of *Uvaria chamae* root extract: Acute and subchronic toxicity studies, J. Afri. Assoc. Physiol. Sci. 4 (1) (2016) 53–60.
[7] M.M. Iwu, Pharmacognostical Profile of Selected Medicinal Plants, Handbook of African Medicinal Plants CRC Press, 2014, pp. 326–327. Available from: https://www.routledgehandbooks.com/doi/10.1201/b16292-4 (accessed 25.12.18).
[8] T. Bulus, S.E. Atawodi, M. Mamman, Acute toxicity effect of the aqueous extract of *Terminalia avicennioides* on white albino rats, Sci. World J. 6 (2) (2011) 1–4.
[9] D. Lorke, A new approach to practical acute toxicity testing, Arch. Toxicol. 54 (4) (1983) 275–287.

[10] OECD, Acute Oral Toxicity: Acute Toxicity Class Method. Test guidelines No. 423, Organization for Economic Co-operation and Development, Paris, 2001.
[11] S. Teo, D. Stirling, S. Thomas, A. Hoberman, A. Kiorpes, V. Khetani, A 90-day oral gavage toxicity study of D-methylphenidate and D, L-methylphenidate in Sprague-Dawley rats, Toxicol 179 (3) (2002) 183–196.
[12] M. Lee, C. Seo, S. Cha, H. Shin, Safety assessment of So-cheong-ryong-tang: Subchronic toxicity study in Crl: CD Sprague Dawley rats, Mol. Med. Rep. 9 (2014) 2273–2282.
[13] I.L. Usende, D. Leitner, E. Neely, J. Connor, J.O. Olopade, The deterioration seen in myelin-related morphophysiology in Vanadium exposed rats is partially protected by concurrent Iron deficiency, Nig. J. Physiol. Sci. 31 (1) (2016) 11–22.
[14] I. Fridovich, Superoxide dismutase: An adaptation to a paramagnetic gas, J. Biol. Chem. 264 (14) (1989) 7761–7764.
[15] H. Aebi, Catalase, in: H. Bergmeyer (Ed.), Methods in Enzymatic analysis, Vol. 2, Academic Press, New York, 1974, pp. 674–684.
[16] G.L. Ellman, Tissue sulfhydryl groups, Arch. Biochem. Biophys. 82 (1959) 70–77.
[17] R. Rukkumani, K. Aruna, P.S. Varma, K.N. Rajasekaran, V.P. Menon VP, Comparative effects of curcumin and an analogue of curcumin on alcohol and PUFA-induced oxidative stress, J. Pharm. Pharm. Sci. 7 (2) (2004) 274–283.
[18] H. Ohkawa, N. Ohishi, K. Yagi, Assay for lipid peroxides in animal tissues by thiobarbituric acid reaction, Anal. Biochem. 95 (2) (1979) 351–358.
[19] M. Sivoňová, Z. Tatarková, Z. Ďuračková, D. Dobrota, J. Lehotský, T. Matáková, P. Kaplán, Relationship between antioxidant potential and oxidative damage to lipids, proteins and DNA in aged rats, Physiol. Res. 56 (6) (2007) 757–764.
[20] N. Akhtar, M.K. Srivastava, R.B. Raizada RB, Assessment of chlorpyrifos toxicity on certain organs in rats, Rattus norvegicus. J. Environ. Biol. 30 (6) (2009) 1047–1053.
[21] J.D. Bancroft, H.C. Cook, Manual of Histological Techniques and their Diagnostic Application, Churchill Livingstone, London, 1994, pp. 289–305.
[22] NRC, Toxicity testing for assessing environmental agents. National Research Council Interim Report, National Academies Press, Washington, DC, 2006.
[23] D.G Maheshwari, N.K. Shaikh NK, An overview on toxicity testing method, Int. J. Pharm. Technol. 8 (2) (2016) 3834–3849.
[24] S.O. Aniagu, F.C. Nwiniyi, D.D. Akumka, G.A. Ajogu, S. Dzarma, K.S. Izebe, M. Ditse, P.E.C. Nwaneri, C. Wambebe, K. Gamaniel, Toxicity studies in rats fed nature cure bitters, Afri. J. Biotechnol. 4 (1) (2005) 72–78.
[25] W.L. Duan, X.M. Liang XM, Technical Guidelines Assembly of Veterinary Medicine Research, Chemical Press, Beijing, 2011.
[26] I.E. Onakpa, Evaluation of *Uvaria chamae* aqueous and ethanolic extracts for activity against multidrug resistant bacteria M.Sc Thesis, Department of Microbiology, University of Nigeria, Nsukka, 2010, p. 96.
[27] H.A. Bila, Phytochemical and antimalaria studies of the leaves of *Uvaria chamae* P. Beau. (Annonaceae) M.Sc Thesis, Department of Pharmaceutical and Medicinal Chemistry, Ahmadu Bello University, Zaria, 2016, p. 69.
[28] E.J. Emeka, A.E. Oluwatoyin, O.I. Adekunle, I.O. Ignis IO, Preliminary phytochemical screening and evaluation of hypoglycaemic properties of the root extract of *Uvaria chamae*, Bangladesh J. Pharmacol. 10 (2015) 326–331.
[29] J.E. Okon, I.R. Udosen, E.O. Mbong, Phytochemical screening and effect of ethanolic root extract of *Uvaria chamae* on albino rats in Akwa Ibom State, Nigeria, Merit Res. J. Environ. Sci. Toxicol. 1 (2) (2013) 16–20.
[30] Y. Piao, Y. Liu, X. Xie X, (2013) Change trends of organ weight background data in Sprague Dawley rats at different ages, J. Toxicol. Pathol. 26 (1) (2013) 29–34.
[31] R.S. Sellers, D. Morton, B. Michael, N. Roome, J.K. Johnson, B.L. Yano, R. Perry, Schafer, Society of Toxicologic Pathology position paper: Organ weight recommendations for toxicological studies, Toxicol. Pathol. 35 (5) (2007) 751–755.
[32] F.E. Olumese, I. Onoagbe, G.I. Eze, F.O. Omoruyi, Subchronic toxicity study of ethanolic extract of *Uvaria chamae* roots in rats, Trop. J. Pharm. Res. 17 (5) (2018) 831, doi:10.4314/tjpr.v17i5.12.
[33] E.O. Okafor, Effects of oral administration of leaf extract of *Uvaria chamae* (mmimi ohia) in albino Wistar rats M.Sc Thesis, Department of Medical Laboratory Sciences. University of Nigeria, Nsukka, 2013, pp. 54–66.